

# GEMSP exerts a myelin-protecting role in the rat optic nerve

Arturo Mangas<sup>1</sup>, Elena Vecino<sup>2</sup>, F. David Rodríguez<sup>3</sup>, Michel Geffard<sup>4,5</sup>, Rafael Coveñas<sup>1</sup>

<sup>1</sup>Institute of Neurosciences of Castilla y León (INCYL), Laboratory of Neuroanatomy of the Peptidergic Systems (Lab. 14), Salamanca, Spain, <sup>2</sup>University of the Basque Country, Department of Cell Biology and Histology, Group of Experimental Ophthalmology-Biology (GOBE), Faculty of Medicine, Leioa, Spain, <sup>3</sup>University of Salamanca, Department of Biochemistry and Molecular Biology, Research Group BMD, Salamanca, Spain, <sup>4</sup>IDRPHT, Talence, France, <sup>5</sup>Gemacbio, St Jean d'Ilac, France

**Objectives:** Chronic experimental autoimmune encephalomyelitis (EAE) was induced in rats to evaluate the potential protective effect of GEMSP, a mixture made up of fatty acids (FA), vitamins, and amino acids or their derivatives, linked to Poly-L-Lysine, on the myelin sheath of the optic nerve.

**Methods:** To evaluate the effects of GEMSP on the optic nerve, animals were divided into three experimental groups: (1) EAE rats treated with GEMSP; (2) EAE rats treated with 0.9% NaCl; and (3) control, non-EAE rats. Using electron microscopy, we investigated the possibility that this new drug candidate has a myelin-protective role.

**Results:** A marginally significant reduction in the thickness of the myelin around optic nerve medium-size axons (diameter between 0.8–1.3  $\mu\text{m}$ ) was found in EAE rats. Treatment of EAE rats with GEMSP ameliorated myelin damage. Significantly increased myelin thickness was found when animals in groups 2 and 3 were compared. However, the number of myelinated axons studied was not altered in groups 1 or 2 when compared to controls.

**Discussion:** Our results suggest that in a model of demyelination, GEMSP protects and enhances the formation of the myelin sheath of the optic nerve and therefore could be a potential drug candidate to reduce optic nerve pathogenesis in multiple sclerosis (MS).

**Keywords:** Demyelination, Experimental autoimmune encephalomyelitis (EAE), Multiple sclerosis (MS), Optic nerve

## Introduction

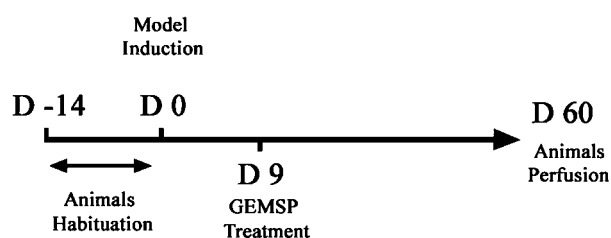
Multiple sclerosis (MS) is a progressive chronic inflammatory autoimmune and neurodegenerative disease affecting the central nervous system (CNS). Its etiology remains unknown. Focal leukocyte infiltration, which produces inflammation, followed by demyelination, axonal degeneration, and loss, results in nerve cell dysfunction.<sup>1,2</sup> As the disease progresses, patients develop multiple disabilities. Multiple sclerosis appears more frequently in young adults (20–45 years of age) and affects twice as many women as men.<sup>3</sup> The highest incidence of onset occurs in the third decade of life. Commonly, MS causes ophthalmologic damage, including optic neuritis, diplopia, bilateral uveitis, oscillopsia, retinal periphlebitis, etc., all of which can severely impair vision.<sup>4,5</sup>

Experimental autoimmune encephalomyelitis (EAE) is an animal model used for the study of MS since many similar clinical and histopathological features can be

observed. Experimental autoimmune encephalomyelitis can be induced by the administration of peptides derived from myelin components, such as myelin basic protein, proteolipid protein, or myelin oligodendrocyte glycoprotein (MOG).<sup>6</sup> Experimental autoimmune encephalomyelitis is widely used for the evaluation of different drugs (beta interferon (IFN-beta), glatiramer acetate (GA), laquinimod, linomide, and GEMSP).<sup>7–13</sup> There are two classical models of EAE: (a) acute EAE, characterized by a clear EAE onset accompanied by inflammation of the CNS for a relatively short duration followed by nearly complete recovery of the animals and (b) chronic EAE, in which the animals present clinical signs for at least 2 months with several EAE relapses. In general, these animals exhibit irreversible damage of the CNS.<sup>10,13</sup> The main advantages of this latter model are that it appears to mimic the pathogenesis of MS since the disease changes over long periods of time and no recovery of the clinical signs are evident.

GEMSP is a recently designed combination of fatty acids (FA), antioxidants, free radical scavengers, and amino acids linked to poly-L-Lysine<sup>14</sup>. This new drug

Correspondence to: David Rodriguez, Department of Biochemistry and Molecular Biology, University of Salamanca, Edificio Departamental, Campus Unamuno, 37007 Salamanca, Spain. Email: lario@usal.es



**Figure 1** Experimental procedure. The main experimental events are represented for a better appreciation of the timing of each manipulation (induction, beginning of treatment, and perfusion). D: day; D-14: arrival date of the animals; D 0: date of model induction; D 9: start of treatment; and D 60: day on which animals were sacrificed.

candidate was originally conceived for the secondary progressive form of MS. Recently, the action of GEMSP was studied on 102 patients suffering from MS.<sup>15</sup> In 72% of cases, a positive improvement in patients treated with GEMSP was observed (amelioration, stabilization of disease evolution, or clear improvement). Moreover, no side effects were detected and the clinical data indicated safety and tolerability. However, these observations should be taken with caution since the study was a clinical follow-up of the patients, and not a randomized controlled trial. In addition, in both EAE models (acute and chronic), GEMSP abolished the onset of EAE, inhibited leukocyte CNS infiltration, and prevented CNS damage. No side effects have been described in the animal models studied. Moreover, GEMSP exerts a myelin-protecting role in the brain and methionine (an amino acid component of GEMSP) has been found inside the motoneurons located in layer IX of the ventral horn of GEMSP-treated EAE rats.<sup>10</sup> These data suggest that GEMSP might be a good candidate for the treatment of MS.

The role of GEMSP in the protection of the myelin sheath of the optic nerve has not previously been investigated. Therefore, in light of the aforementioned data, we studied the optic nerve of chronic EAE animals using electron microscopy and analyzed axonal loss, the degree of demyelination, and the putative myelin-protecting effect of GEMSP. We have chosen the optic nerve to evaluate the effect of GEMSP since a large number of MS patients display ophthalmologic damage.<sup>5</sup>

## Materials and Methods

### Animals

In this study, 18 Lewis 1A female rats aged 10–11 weeks (weighing approx 190 g), obtained from CERJ Janvier (St Berthevin, France) were used. The animals were kept under standardized light and temperature conditions and had free access to food and water. The rats remained in their cages for at least 2 weeks (adaptation period) prior to experimentation (D -14) (see Fig. 1).

### Synthesis of GEMSP

GEMSP was synthesized according to patent numbers 6114388 (USA) and 792167 (EU). This drug is a tailor-made combination of different compounds linked to Poly-L-Lysine via glutaraldehyde, glutaric anhydride, or amide bonds.<sup>16</sup> The components of GEMSP are detailed in Table 1.

### Induction of EAE

Chronic EAE induction was performed on day 0 (D 0, see experimental procedure, Fig. 1) in groups 1 and 2 (see below). Each rat from these groups was immunized with 50 µg of MOG, purified at the laboratory of Professor Villoslada (Pamplona, Spain).<sup>17</sup> Myelin oligodendrocyte glycoprotein was combined with Freund's adjuvant (ACF, Sigma), to which 200 µg of heat-inactivated *Mycobacterium tuberculosis* H37RA (Difco) was added. The rats were anaesthetized with isoflurane. The MOG solution was injected once, intradermally, at the base of the tail.

### Animal groups and clinical evaluation of EAE

Two groups of animals were immunized on D 0: (1) EAE-immunized rats treated with GEMSP ( $n = 8$ ) and (2) EAE-immunized rats treated with NaCl (0.9%) ( $n = 8$ ). A third group of animals was not immunized (non-EAE-immunized rats treated with NaCl) (control) ( $n = 2$ ).

The animals were weighed and scored, according to a previously described scale,<sup>18</sup> 6 days/week throughout the experiments by two alternating investigators. The neurological signs of EAE, which started around day 15 after induction, were assessed and scored using the following scale: 0, no signs; 1, tail weakness

**Table 1** GEMSP components

Families	PLL components
Fatty acids	Azelaic acid-PLL-Oleic acid Azelaic acid-PLL-Palmitoleic acid Farnesyl-L-Cysteine-PLL-Oleic acid Farnesyl-L-Cysteine-PLL-Palmitic acid Linoleic acid-PLL Oleic acid-PLL-Cholesterol Oleic acid-PLL-Linoleic acid Oleic acid-PLL-Myristic acid Oleic acid-PLL-Palmitic acid Oleic acid-PLL-Palmitoleic acid Oleic acid-PLL-Thioctic acid
Antioxidants	alpha-Tocopherol-succinate-PLL Ascorbic acid-PLL
Amino acids And Derivatives	L-Methionine-G-PLL L-Cysteine-G-PLL Taurine-G-PLL Histamine-GA-PLL L-Histidine-GA-PLL 5-Methoxytryptamine-GA-PLL

Different families of GEMSP components. The treatment took place under identical conditions throughout the experiments, using the same lot number. Lyophilized GEMSP was reconstituted in sterile water before subcutaneous injection. G: reduced glutaraldehyde; GA: glutaric anhydride; PLL: Poly-L-Lysine. The final concentration of GEMSP components, in molarity (M), was between  $10^{-3}$  M and  $10^{-4}$  M.

or tail paralysis; 2, hind leg paraparesis or hemiparesis; 3, hind leg paralysis or hemiparalysis; and 4, complete paralysis (tetraplegy).

Drug or control treatments began 9 days after the induction of chronic EAE (D 9, see Fig. 1). Since day 9 (D 9) all animals received a single daily subcutaneous injection of the respective solution (saline or GEMSP). Animals in group 1 were treated with 7.5 mg of GEMSP per day (dissolved in 0.5 ml of saline solution) and animals in group 2 received 0.5 ml of saline solution per day. After 51 days of treatment (D 60 in Fig. 1) the animals were sacrificed for study. The experimental design, protocols, and procedures used in this work were performed under the guidelines of the ethics and legal recommendations of Spanish, French, and European legislations. This work was also approved by the Bioethics Committee of the University of Salamanca (Spain).

### *Histological evaluation of spinal cords and optic nerves*

Following the perfusion of the animals in the three experimental groups (Fig. 1), the spinal cords were dissected out, placed in 4% paraformaldehyde in 0.1 M phosphate-buffer (PB), pH 7.2 at 4°C for 12–16 hours and immersed in increasing concentrations of sucrose (from 5 to 30%). Around 10–15  $\mu\text{m}$ -thick sections of the spinal cords were obtained using a freezing microtome and were processed for Nissl, Luxol fast Blue, or Haematoxylin-Eosin.<sup>16</sup> Spinal cord leukocyte infiltration was visualized with the monoclonal anti-rat CD 45 leukocyte marker (purchased from Serotec or Pharmingen and diluted 1/500) and evaluated by semiquantitative analysis (absence of leukocytes, low density of leukocytes, and high density of leukocytes).<sup>10</sup> Demyelination was semiquantitatively estimated (traces of demyelination, marked demyelination and extensive demyelination).<sup>18</sup>

On D 60 (Fig. 1) animals were deeply anaesthetized with urethane (1 g/kg, intraperitoneally), heparinized, and perfused via the ascending aorta with 50–100 ml of cold physiological saline (0.9% NaCl) and with 500 ml of cold 4% paraformaldehyde prepared in PB (10 minutes). The optic nerves (the region proximal to the eye) were excised and processed for electron microscopy.

### *Electron microscopy*

After extraction, the optic nerves were post-fixed for 12 hours in 2% paraformaldehyde, prepared in PB, containing 2% glutaraldehyde. The nerves were then washed twice with PB and kept in PB for 12 hours. Samples were post-fixed in 1% osmium tetroxide for 2 hours and washed twice in PB at 1 hour intervals. Samples were dehydrated using an increasing acetone gradient. Following 1 hour in 100% acetone, the

specimens were treated twice for 30 minutes with propylene oxide at 4°C. The nerves were embedded in EPON Polarbed 812<sup>TM</sup> (epoxy resin); first using a mixture of propylene oxide and EPON (1:1, by volume) for 60 minutes at room temperature followed by impregnation in EPON for 24 hours and encapsulation and polymerization in resin for 24 hours at 60°C.

After polymerization, the EPON blocks were trimmed, sectioned thinly (0.5  $\mu\text{m}$ ) and stained with 1% toluidine blue in 1% sodium borate. Ultrathin sections (80 nm) were contrasted with uranyl acetate and lead citrate and observed with a Phillips 301 electron microscope. Sections were photographed for subsequent analysis.

### *Quantification studies*

Five photographs ( $\times 6300$ ) were taken from each optic nerve in all experimental groups studied. Fields without blood vessels or glial cells were selected. Photographs were digitalized using the program WCIF Image J (Bethesda, Maryland, USA.). To minimize errors caused by the differences in diameter, the number of medium-size axons (diameter between 0.8 and 1.3  $\mu\text{m}$ ) per field (100  $\mu\text{m}^2$ ), in transversal sections of the optic nerve, was counted in all experimental groups. The thickness of myelin was also measured in medium-size axons. Single-blind measurements were taken. Results from each experimental group were pooled and expressed as the mean  $\pm$  SEM. Statistical differences between groups were assessed by using the non-parametric Mann–Whitney U test. (Statistical analysis was done with the program Vassart Stats: [www.vassartsats.net](http://www.vassartsats.net)).

## **Results**

### *Clinical score*

Several factors must be considered when using EAE models. An important consideration is the clinical score of the animals and their clinical evolution. In our study, the animals were weighed and observed daily (6 days a week) by different researchers to preserve objectivity. Neither the animals in group 1 (EAE-immunized rats treated with GEMSP) nor those in group 3 (non-EAE-immunized rats treated with NaCl) (control) showed EAE clinical signs. This means that none of the animals in either group developed EAE. This was expected in group 3 because the animals had not been subjected to EAE induction. However, animals in group 1 were induced with the same solution as animals in group 2, indicating that the absence of EAE in group 1 might be associated with the GEMSP treatment.

Clinical evaluation of the EAE induced animals (group 2, treated with NaCl) showed, at the time of perfusion, a clinical score of 1.5 (median) with a range between 0.5 and 4. This result is in accordance

with previously published data.<sup>10,18</sup> Some animals started with a score of 1 and maintained the same score until the end of the experiment (2 months after induction). Other animals started with a score of 3 that was maintained until the end of the experiment. A third group of animals developed a progressive model starting with a score of 1 or 2, which progressed up to 4 in a variable period. As previously mentioned, the clinical score of the animals belonging to groups 1 (EAE-immunized and treated with GEMSP) and 3 (non immunized animals) was 0.

### *Histology of the spinal cord*

The spinal cords of the animals in the three experimental groups were studied. Spinal cord histology in the control group was found normal and no leukocyte infiltration was observed. Animals treated with EAE-NaCl showed high leukocyte infiltration and extensive demyelination. However, in EAE animals treated with GEMSP leukocyte infiltration was low and only traces of demyelination were observed, compared to control and NaCl-treated animals. This observation correlates well with the observed clinical scores. Also, the research agrees with the findings reported by Weissert *et al.*<sup>18</sup>

### *Effect of GEMSP on the axons of the optic nerve in EAE-treated animals*

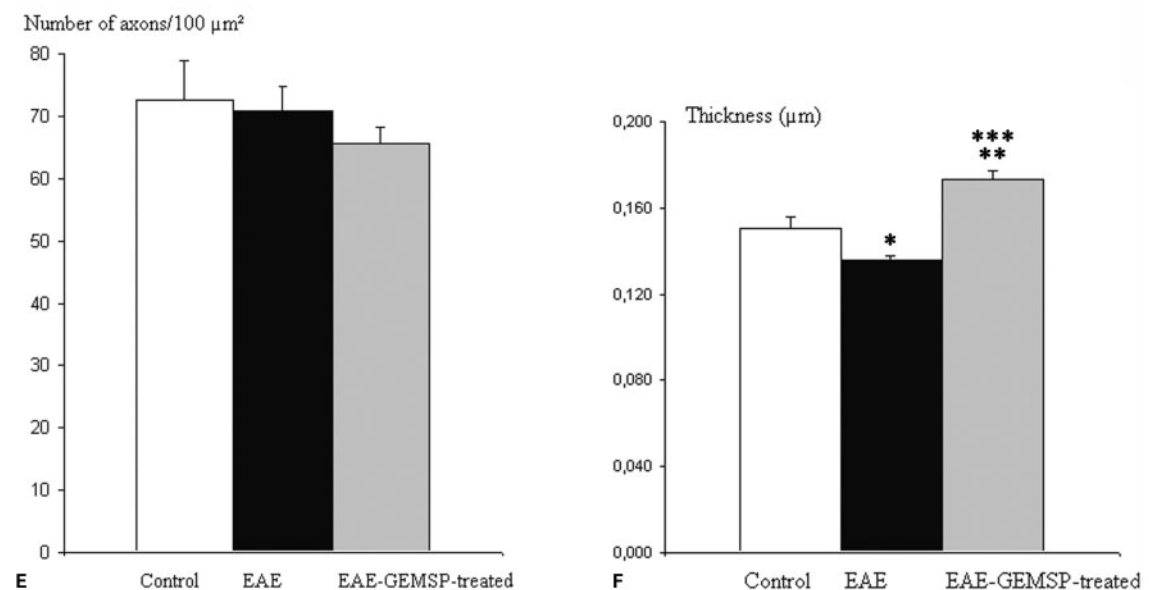
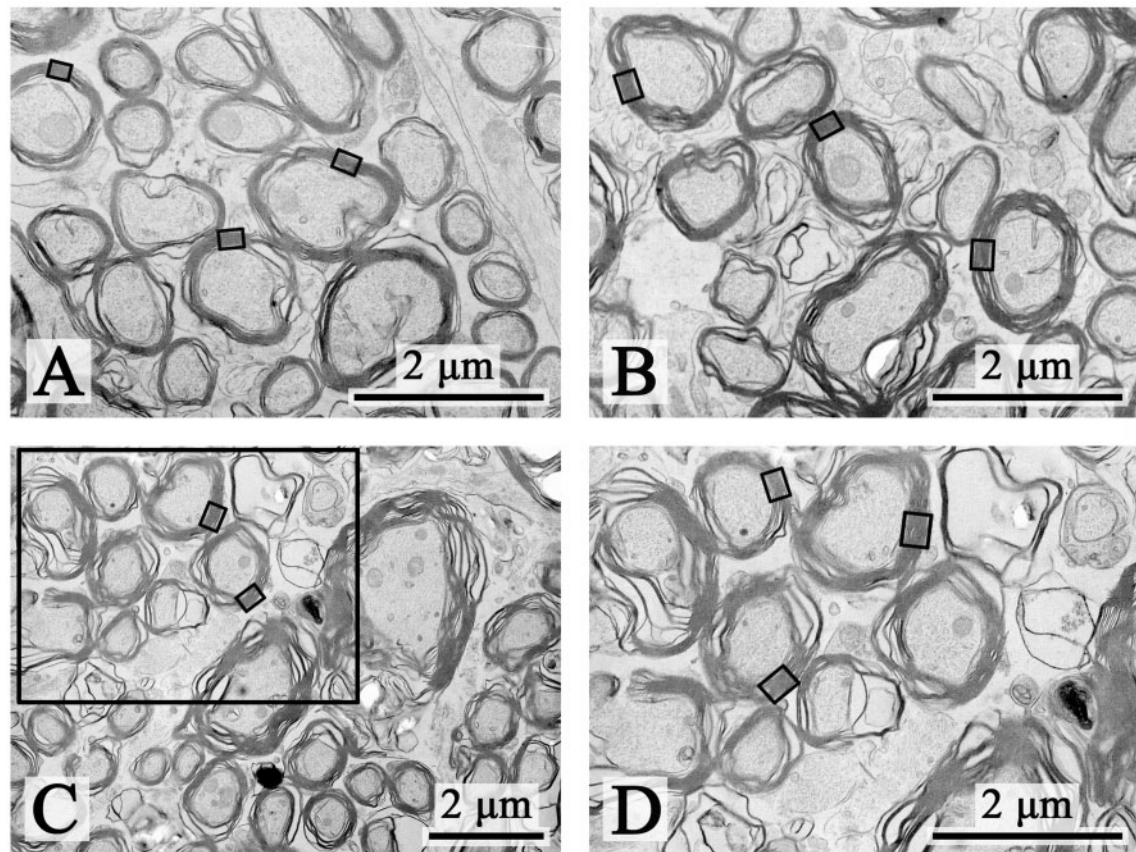
Two parameters were evaluated in the optic nerve sections to study the efficacy of GEMSP in a chronic EAE model: (1) the number of myelinated axons per 100  $\mu\text{m}^2$ ; and (2) axon myelin thickness (Fig. 2). No edema was observed in the animals after perfusion. To eliminate erroneous measurements, due to differences in diameter or irregular shape, the most abundant and homogenous population of so-called medium-size axons (diameter between 0.8–1.3  $\mu\text{m}$ ) was selected (Fig. 2). Also, very warped or distorted axons were discarded. The number of axons in a 100  $\mu\text{m}^2$  surface (transversal section) did not change significantly in the EAE group treated with saline or in the EAE group treated with GEMSP (Fig. 2E), when compared to controls. However, the thickness of the myelin sheath was slightly but significantly reduced in EAE-NaCl animals (Fig. 2F) compared with control animals. This means that a demyelination event occurred in this group. Interestingly, EAE rats treated with GEMSP showed a significantly augmented electron dense myelin cover compared to both control and EAE-NaCl rats (control:  $0.150 \pm 0.005 \mu\text{m}$ ; EAE-NaCl:  $0.136 \pm 0.004 \mu\text{m}$ ; and EAE-treated with GEMSP:  $0.173 \pm 0.006 \mu\text{m}$ . Values are expressed as mean  $\pm$  SEM, see Fig. 2F). Calculated *P* values were as follows: *P* < 0.05, control group compared with EAE group treated with saline; *P* < 0.001, control group compared with

EAE-GEMSP-treated group; and *P* < 0.0001, EAE-treated with saline and EAE-GEMSP-treated group.

## **Discussion**

Using an animal model of MS showing spinal cord histological alterations, we report, for the first time, that, in the optic nerve, myelin damage was less pronounced after GEMSP treatment of EAE-sick rats and myelin thickness was significantly increased when compared with both control animals and EAE-NaCl-treated animals. In order to appreciate such changes quantification was carried out, since the variations observed in the thickness of the myelin sheath could not be visualized by eye. Our study was carried out using the most abundant and homogenous population of myelinated axons (denominated medium-size axons) located in the optic nerve, so that erroneous estimates of the parameters measured could be avoided.

We have found that the number of myelinated medium-sized axons in the optic nerve did not significantly change in EAE animals (treated with NaCl or GEMSP) in comparison with control animals. Thus, we did not observe a significant axonal loss in the optic nerve in both the EAE animals and the EAE-GEMSP-treated ones. Concerning the kinetics of retinal ganglion cell death in a rat EAE model, it has been suggested that loss of these neuronal cells happens prior to clinical onset and was linked to both a down-regulation of phospho-Akt and a shift in the Bcl-2 family members, Bax and Bcl-2, indicating a disrupted balance of pro- and anti-apoptotic molecules.<sup>19–21</sup> These studies show that myelin destruction and neuronal damage take place simultaneously in experimental models of autoimmune demyelination, and emphasize the critical role of invading inflammatory immune cells. It has been suggested that axonal damage is either induced by inflammation itself or is a consequence of demyelination, and that neuronal death could occur secondarily to axonal damage or, primarily, in the course of inflammation. Here, in the chronic EAE model, we have observed demyelination, but not significant axonal loss 60 days after induction of EAE. In a brown Norway rat model of MS that frequently leads to optic neuritis, it has been reported that before leukocyte infiltration the innate immune system plays a critical role in mediating early neurodegeneration.<sup>22</sup> In fact, degeneration of both axons and retinal ganglion perikarya were reported. Similarly, after using spectral domain optical coherence tomography (a potent tool for the detection of retinal neurodegeneration) in patients suffering MS it has been shown that retinal axonal loss begins early in the progression of MS and increases in advanced stages of the disease. Neuroaxonal retinal damage occurs in MS subtypes and a significant but limited



**Figure 2** Electron microscopy of myelinated axons located in the optic nerve and belonging to the three experimental groups studied (A–D). (A) EAE-immunized animals treated with NaCl (B) non-EAE-immunized animals (C) EAE-immunized animals treated with GEMSP. A high-power magnification of the region delimited in C is observed in (D). In A–D, small rectangles show examples of the measured myelin sheath (E) number of myelinated medium-size axons (diameter between 0.8 and 1.3  $\mu\text{m}$ ) per 100  $\mu\text{m}^2$  in optic nerve transversal sections from control, EAE, and EAE-GEMSP-treated rats. The results are expressed as mean  $\pm$  SEM of at least five measurements in each experimental group. No significant differences were found when comparing the three groups (by using the non-parametric Mann–Whitney U test). (F) Thickness of the myelin cover in medium-size axons (0.8–1.3  $\mu\text{m}$  of diameter) from optic nerve sections quantified in control, EAE, and EAE-GEMSP-treated rats. Results are expressed as mean  $\pm$  SEM of at least 90 measurements in each experimental group. Asterisks denote statistical significance assessed by the non-parametric Mann–Whitney U test (\*  $P < 0.05$ , when comparing control with EAE-NaCl-treated group; \*\*  $P < 0.001$ , when comparing control and EAE-GEMSP-treated group; and \*\*\*  $P < 0.0001$ , when comparing EAE-NaCl and EAE-GEMSP-treated groups).

association of retinal neuroaxonal damage with brain atrophy exists in MS.<sup>23–29</sup> Altogether these studies show that neuroretinal axonal loss occurs in patients suffering from MS. Consequently, the significance of the increased myelin thickness, observed here after GEMSP treatment, has to be analyzed with caution since no direct relationship between this observation and functional recovery can be established. This could represent a limitation of our study since the observed increase of the myelin sheath caused by GEMSP may not attenuate the visual impairment of these patients. However, clinical trials should be developed to demonstrate this. Additionally, the possible neuroprotective action of GEMSP should be tested in a chronic EAE animal model of MS.

Previously, it has been shown that the brain leukocyte infiltration in the chronic EAE model is high and widespread when the first EAE clinical attack occurs. There was found to be less leukocyte infiltration in later stages of the disease (days 60–100 after EAE induction), although the clinical signs persisted.<sup>10,30</sup> In the present study the animals were perfused 60 days after the induction of EAE, a time when the infiltration is considerably reduced.<sup>10</sup> Disease pathogenesis in classical neurodegenerative diseases, such as Alzheimer's, can be directly attributed to the levels of CNS inflammation; which can also contribute to acute neuronal cell death. Thus, a clearer understanding of the progression of these damaging events may be beneficial for MS research and also for other diseases that are primarily non-inflammatory.

#### *Effects of the GEMSP dose on EAE*

It has previously been reported<sup>10,16</sup> that the administration of low doses (0.75 mg per day) of GEMSP considerably reduces brain leukocyte infiltration, although no effect against the development of EAE was observed. To determine the optimal dose exhibiting the maximum effect, a dose-range study was previously carried out in both acute and chronic EAE models.<sup>10,16</sup> The results showed that the dose used here (7.5 mg per day) completely abolished acute and chronic EAE episodes. We observed that there was a true dose-response effect on EAE clinical attack, since lower doses (3.75 mg per day) were not as effective in abolishing EAE crises, and doses of 0.75 mg/day and 1.875 mg/day were not effective at all against the EAE crises.<sup>16</sup> At a dose of 3.75 mg a day, GEMSP seems to exert a strong reduction, but did not completely abolish, EAE episodes in the acute EAE model. For the aforementioned reasons, in this study, we administered the higher dose (7.5 mg/day).<sup>16</sup> The results reported here suggest that long-term treatment with GEMSP completely abolishes the development of EAE in a chronic model of the

disease. This is in agreement with previous studies<sup>14</sup> where GEMSP doses ranging from 0.75 to 7.5 mg/day were tested. The results found point to a beneficial effect of GEMSP in patients suffering from MS.

The toxicity of GEMSP has been analyzed by GEMACBIO (Saint Jean d'Illac, France) as well as by an independent laboratory (EVIC, France).<sup>16</sup> The results revealed zero mortality in animals after a single intravenous dose of 10 mg/kg (LD<sub>0</sub> and LD<sub>50</sub>>10 mg/kg). The doses applied in the toxicity study were lower than those used in the present study. In addition, previous pharmacokinetic studies have demonstrated that the components of the GEMSP can be detected in serum for at least 24 hours after a single subcutaneous injection. Moreover, serum concentration peak of GEMSP components was found 2 hours after the administration of GEMSP.<sup>16</sup>

#### *Clinical score*

Clinical signs in the animals belonging to group 2 (EAE-treated with NaCl) have been observed, which highlights the complexity of the chronic EAE model. The variability observed in this model also reflects the intricacy of the pathogenic processes involved the experimentally induced disease.<sup>10</sup> This variability can also be observed in MS patients. Accordingly, each animal or patient must be considered as a single immune entity. Clinical signs were not detected in all the EAE animals treated with GEMSP. This finding is in agreement with a previous report in which the chronic EAE model was developed.<sup>31</sup> It is known that some chronic EAE animals (approximately 10–15%) show no clinical signs of the disease. Whilst this point has been taken into consideration, the probability that all eight animals in group 1 were unresponsive to the induction of EAE is very low.

#### *Spinal cord histology*

The rat spinal cords were studied to confirm that the disease was induced in EAE animals (treated or not treated with GEMSP). The application of several histological techniques allowed us to observe tissue damage in the spinal cords of those animals. The damage (demyelination and leukocyte infiltration) was greater in EAE-NaCl-treated rats compared to EAE-GEMSP-treated rats (as assessed by semiquantitative analysis). The data are similar to results obtained in previous reports using the same experimental model.<sup>10,18,30</sup>

#### *Effects of GEMSP on the myelin sheath*

Axonal injury and neuronal loss, which are initiated in the early phases of MS, play an important role in determining the extent of permanent neurological disability. It has been reported recently that GEMSP could decrease demyelination processes in

EAE animals.<sup>32</sup> This study was carried out in the intercollicular commissure using an immunocytochemical technique (anti-myelin basic protein) to visualize the myelin sheath. When marked (immunoreactive)/non-marked (non-immunoreactive) surface was measured the values in percentage were 20.06% in control animals, 12.01% in EAE animals treated with GEMSP, and 5.91% in non-treated EAE animals. This preliminary study suggests that GEMSP reduces demyelination processes in the brain. These results are consistent with the results of the present study. Additionally, we have shown that GEMSP increases the thickness of the myelin sheath surrounding optic nerve axons.

#### *Possible roles of the components of GEMSP*

Multiple sclerosis is characterized by demyelination, a fluctuating loss of oligodendroglial cells and axonal degeneration. It would appear that chronic demyelination leads to gradual axonal death, which is probably a contributing factor to the progressive form of MS. Hence, current MS treatments, which are preferentially immunomodulatory, should be complemented with therapies aimed to prevent demyelination, not only to restore conduction velocity but also to prevent irreversible axonal damage.<sup>33</sup> In this context, the most promising long-term strategy would be early intervention with anti-inflammatory therapies as well as with protective therapies that prevent oligodendrocyte and axonal injury.

The mechanisms underlying the observed effects of GEMSP are largely unknown. Certainly, the heterogeneous composition of GEMSP makes it difficult to unravel the role of the components in isolation or in combination. For example, 5-methoxytryptamine, one of the components of GEMSP, is a structure related to melatonin (a molecule that exhibits anti-amylogenic properties),<sup>34</sup> and carnosine and homocarnosine have potential neuroprotective properties.<sup>35</sup> The effects of other components may act through mechanisms influencing the electrical function, the cerebral blood flow, or the autoimmune response, among other phenomena.<sup>36,37</sup> Further studies are required to determine the encouraging outcomes reported here.

Reactive oxygen species (ROS) have been implicated in demyelination events and in axonal damage related to MS. Reactive oxygen species cause damage to lipids, proteins, and nucleic acids, resulting in cell death by necrosis or apoptosis.<sup>30</sup> The administration of antioxidants to EAE animals decreases the adverse clinical signs, suggesting that antioxidants may support cellular antioxidant defences by scavenging free radicals and/or by interfering with gene transcription, protein expression or enzyme activity.<sup>38</sup> Antioxidants are categorized as either scavengers or prevention antioxidants. Scavengers (e.g., vitamin C)

remove ROS, whereas prevention antioxidants (e.g., taurine, methionine, melatonin, and cysteine) hinder the formation of new ROS. Some vitamins and some molecules containing thiol groups (cysteine, for instance) inhibit apoptotic mechanisms.<sup>39–41</sup> Therefore, the use of antioxidants might theoretically prevent the propagation of tissue damage and improve both survival and neurological outcome.<sup>42</sup> The combination of GA and the main phenol found in green tea (the epigallocatechin-3-gallate, or EGCG) may also be a promising strategy for the treatment of MS. In fact, this combination tested *in vitro* inhibited neural death and promoted axonal growth, whereas in an EAE animal model the association of both compounds delayed the disease onset and reduced the clinical severity and the inflammatory infiltrates.<sup>43</sup>

Deficiencies in essential FA can seriously impair myelin synthesis.<sup>44</sup> It is therefore possible that the FA present in GEMSP could be involved in the process of remyelination observed here. Moreover, oleic acid, one of the components of GEMSP, behaves as a neurotrophic factor in neurons.<sup>45</sup>

Taking this data into consideration and with the aim of controlling oxidative processes, antioxidants (vitamins, amino acids, and thiol derivatives) as well as anti-inflammatory elements (FA)<sup>15</sup> were included in GEMSP to achieve better efficiency. GEMSP is a mixture of different molecules linked to poly-L-lysine by reduced glutaraldehyde linkages that achieve very flexible bonds (free conformation in space improves interactions and facilitates the access to the lesion site).<sup>31</sup> Linkage to poly-L-lysine offers other advantages as well. For instance, it prevents metabolic degradation and hence increases the half-life of the therapeutic components. It also permits the administration of small amounts of beneficial antioxidants and, consequently, improves free radical scavenging.

In a small sized open phase IIa clinical trial ( $n = 22$ ), carried out in humans with secondary progressive MS, patients received low doses of GEMSP (0.75 mg/day, sublingual route) for 6 months. Expanded disability status scale (EDSS) value was determined before and after GEMSP treatment in each patient. A stable EDSS value was maintained by 55% of the patients and 18% had decreased EDSS values, instead of a normal progression of 0.25 points on the mean EDSS scale.<sup>14</sup> No side effects were reported and GEMSP did not elicit neither biological, nor hematological or hepatic side effects.<sup>16,30</sup> These results are in agreement with a follow-up study in which 102 patients suffering from MS were treated with GEMSP (2–6 mg/day). In 72% of patients a decrease or stabilization of the disease evolution or an improvement of the disease was observed.<sup>15</sup> Clinical state worsened in 28% of patients (they did not respond to the treatment and the average

worsening of disability was of 0.97 points/year) and 20% of the subjects in this study exhibited a decrease in the progression of the disease (reduction of 45.6%). Disease stabilization was observed in 17% of patients and 35% presented improvement in their state (0.918 points/year).

In conclusion, we have found that in the chronic EAE model the number of myelinated medium-sized axons of the optic nerve did not change significantly, but the myelin cover was reduced. Interestingly, the treatment of EAE animals with GEMSP increased myelin thickness over control measurements. This suggests that GEMSP has an active role in the control of the formation of the myelin sheath. Further studies are needed to ascertain the precise implication of GEMSP in the events related to the formation and maintenance of the myelin that covers the axons forming the optic nerve. The data reported here and in previous work<sup>10,13,16</sup> suggest that GEMSP may be considered as a new potential drug candidate for the treatment of MS, since it abolishes crises in acute and chronic EAE models, lowers brain leukocyte infiltration, decreases demyelination in the brain, and increases the thickness of the myelin sheath in the optic nerve. Further studies are required to establish the effect of GEMSP on the ophthalmologic damage observed in MS and its possible neuroprotective role.

### Acknowledgements

This work has been supported by GEMACBIO (St Jean d'illac, France), the Institut pour le Developpement de la Recherche en Pathologie Humaine et Therapeutique (IDRPHT) (Talence, France), Red de Terapia Celular de Castilla y León (Spain), Consejería de Educación de la Junta de Castilla y León (Spain) (Ref.: SA099A08), the INCYL-Federación de Cajas de Ahorro de Castilla y León (Spain) and Ministerio de Educación y Ciencia (Spain) (Ref.: SA F2007-62060), Grupos Consolidados del Gobierno Vasco (2010-2015), RETICS Red Patología Ocular RD07/0062, BIOEF08/ER/006. The technical assistance of Ms Belén Armario is gratefully acknowledged. The authors gratefully acknowledge Dr Jennifer Higginson for the English revision of the manuscript.

### References

- Tallantyre EC, Bo L, Al-Rawashdeh O, Owens T, Polman CH, Lowe JS, *et al.* Clinico-pathological evidence that axonal loss underlies disability in progressive multiple sclerosis. *Mult Scler.* 2010;16:406–11.
- Vogt J, Paul F, Aktas O, Müller-Wiensch K, Dörr J, Dörr S, *et al.* Lower motor neuron loss in multiple sclerosis and experimental autoimmune encephalomyelitis. *Ann Neurol.* 2009;66:310–22.
- Trojano M, Lucchese G, Graziano G, Taylor BV, Simpson S Jr, Lepore V, *et al.* Geographical variations in sex ratio trends over time in multiple sclerosis. *PLoS One.* 2012;7:e48078.
- Chen L, Gordon LK. Ocular manifestations of multiple sclerosis. *Curr Opin Ophthalmol.* 2005;16:315–20.
- Roodhooft JM. Ocular problems in early stages of multiple sclerosis. *Bull Soc Belge Ophtalmol.* 2009;313:65–8.
- Fridkis-Hareli M, Santambrogio L, Stern JN, Fugger L, Brosnan C, Strominger JL. Novel synthetic amino acid copolymers that inhibit autoantigen-specific T cell responses and suppress experimental autoimmune encephalomyelitis. *J Clin Invest.* 2002;109:1635–43.
- Aharoni R, Teitelbaum D, Leitner O, Meshorer A, Sela M, Arnon R. Specific Th2 cells accumulate in the central nervous system of mice protected against experimental autoimmune encephalomyelitis by copolymer 1. *Proc Natl Acad Sci U S A.* 2000;97:11472–7.
- Brunmark C, Runstrom A, Ohlsson L, Sparre B, Brodin T, Aström M, *et al.* The new orally active immunoregulator laquinimod (ABR-215062) effectively inhibits development and relapses of experimental autoimmune encephalomyelitis. *J Neuroimmunol.* 2002;130:163–72.
- Floris S, Ruuls SR, Wierinckx A, van der Pol SM, Döpp E, van der Meide PH, *et al.* Interferon-beta directly influences monocyte infiltration into the central nervous system. *J Neuroimmunol.* 2002;127:69–79.
- Mangas A, Covenas R, Bodet D, de Leon M, Duleu S, Geffard M. Evaluation of the effects of a new drug candidate (GEMSP) in a chronic EAE model. *Int J Biol Sci.* 2008;4:150–60.
- Teitelbaum D, Aharoni R, Klingler E, Kreitman R, Raymond E, Malley A, *et al.* Oral glatiramer acetate in experimental autoimmune encephalomyelitis: Clinical and immunological studies. *Ann N Y Acad Sci.* 2004;1029:239–49.
- van der Meide PH, de Labie MC, Ruuls SR, Groenestein RJ, Botman CA, Olsson T, *et al.* Discontinuation of treatment with IFN-beta leads to exacerbation of experimental autoimmune encephalomyelitis in lewis rats. rapid reversal of the antiproliferative activity of IFN-beta and excessive expansion of autoreactive T cells as disease promoting mechanisms. *J Neuroimmunol.* 1998;84:14–23.
- Geffard M, Duleu S, Bessede A, Vigier V, Bodet D, Mangas A, *et al.* GEMSP: a new therapeutic approach to multiple sclerosis. *Cent Nerv Syst Agents Med Chem.* 2012;12:173–81.
- Mangas A, Covenas R, Geffard M. New drug therapies for multiple sclerosis. *Curr Opin Neurol.* 2010;23:287–92.
- Geffard M, de Bisschop L, Duleu S, Hassaine N, Mangas A, Covenas R. Endotherapy: a new frontier in the treatment of multiple sclerosis and other chronic diseases. *Discov Med.* 2010;10:443–51.
- Mangas A, Covenas R, Bodet D, Dabadie MP, Glaize G, Geffard M. Evaluation of the effects of a new drug on brain leukocyte infiltration in an experimental model of autoimmune encephalomyelitis. *Lett Drug Des Discov.* 2006;3:138–48.
- Villoslada P, Abel K, Heald N, Goertsches R, Hauser SL, Genain CP. Frequency, heterogeneity and encephalitogenicity of T cells specific for myelin oligodendrocyte glycoprotein in naive outbred primates. *Eur J Immunol.* 2001;31:2942–50.
- Weissert R, Wallstrom E, Storch MK, Steffler A, Lorentzen J, Lassmann H, *et al.* MHC haplotype-dependent regulation of MOG-induced EAE in rats. *J Clin Invest.* 1998;102:1265–73.
- Aktas O, Waiczies S, Zipp F. Neurodegeneration in autoimmune demyelination: Recent mechanistic insights reveal novel therapeutic targets. *J Neuroimmunol.* 2007;184:17–26.
- Bjartmar C, Wujek JR, Trapp BD. Axonal loss in the pathology of MS: consequences for understanding the progressive phase of the disease. *J Neurol Sci.* 2003;206:165–71.
- Hobom M, Storch MK, Weissert R, Maier K, Radhakrishnan A, Kramer B, *et al.* Mechanisms and time course of neuronal degeneration in experimental autoimmune encephalomyelitis. *Brain Pathol.* 2004;14:148–57.
- Fairless R, Williams SK, Hoffmann DB, Stojic A, Hochmeister S, Schmitz F, *et al.* Preclinical retinal neurodegeneration in a model of multiple sclerosis. *J Neurosci.* 2012;32:5585–97.
- Gelfand JM, Goodin DS, Boscardin WJ, Nolan R, Cuneo A, Green AJ. Retinal axonal loss begins early in the course of multiple sclerosis and is similar between progressive phenotypes. *PLoS One.* 2012;7:e36847.
- Oberwahrenbrock T, Schippling S, Ringelstein M, Kaufhold F, Zimmermann H, Keser N, *et al.* Retinal damage in multiple sclerosis disease subtypes measured by high-resolution optical coherence tomography. *Mult Scler Int.* 2012;2012:530305.
- Zimmermann H, Freing A, Kaufhold F, Gaede G, Bohn E, Bock M, *et al.* Optic neuritis interferes with optical coherence



- tomography and magnetic resonance imaging correlations. *Mult Scler.* 2013;19(4):443–50.
- 26 Dorr J, Wernecke KD, Bock M, Gaede G, Wuerfel JT, Pfueller CF, et al. Association of retinal and macular damage with brain atrophy in multiple sclerosis. *PLoS One.* 2011;6:e18132.
  - 27 Saidha S, Syc SB, Durbin MK, Eckstein C, Oakley JD, Meyer SA, et al. Visual dysfunction in multiple sclerosis correlates better with optical coherence tomography derived estimates of macular ganglion cell layer thickness than peripapillary retinal nerve fiber layer thickness. *Mult Scler.* 2011;17:1449–63.
  - 28 Brandt AU, Oberwahrenbrock T, Ringelstein M, Young KL, Tiede M, Hartung HP, et al. Primary retinal pathology in multiple sclerosis as detected by optical coherence tomography. *Brain.* 2011;134:e193; author reply e194.
  - 29 Bock M, Brandt AU, Dorr J, Pfueller CF, Ohlraun S, Zipp F, et al. Time domain and spectral domain optical coherence tomography in multiple sclerosis: a comparative cross-sectional study. *Mult Scler.* 2010;16:893–6.
  - 30 Mangas A, Covenas R, Bodet D, Duleu S, Geffard M. A new drug candidate (GEMSP) for multiple sclerosis. *Curr Med Chem.* 2009;16:3203–14.
  - 31 Mangas A, Covenas R, Bodet D, Geffard M. Antisera and immunocytochemical techniques. In: Mangas A; Covenas R, Geffard M (eds.) *Brain molecules: from vitamins to molecules for axonal guidance.* Trivandrum: Transworld Research Network; 2008, 1–25.
  - 32 Covenas R, Mangas A, Jaulain C, Geffard M. Multiple sclerosis. In: Sugaya K and Samsam M, (eds.) *Molecular and clinical neuroscience.* Plymouth: McNeil, in press.
  - 33 Althaus HH. Remyelination in multiple sclerosis: A new role for neurotrophins? *Prog Brain Res.* 2004;146:415–32.
  - 34 Reiter RJ. Potential biological consequences of excessive light exposure: Melatonin suppression, DNA damage, cancer and neurodegenerative diseases. *Neuro Endocrinol Lett.* 2002;23 (Suppl.2):9–13.
  - 35 Teufel M, Saudek V, Ledig JP, Bernhardt A, Boularand S, Carreau A, et al. Sequence identification and characterization of human carnosinase and a closely related non-specific dipeptidase. *J Biol Chem.* 2003;278:6521–31.
  - 36 Gillson G, Wright JV, DeLack E, Ballasiotes G. Transdermal histamine in multiple sclerosis: part one – clinical experience. *Altern Med Rev.* 1999;4:424–8.
  - 37 Wuerfel J, Paul F, Zipp F. Cerebral blood perfusion changes in multiple sclerosis. *J Neurol Sci.* 2007;259:16–20.
  - 38 van Meeteren ME, Teunissen CE, Dijkstra CD, van Tol EA. Antioxidants and polyunsaturated fatty acids in multiple sclerosis. *Eur J Clin Nutr.* 2005;59:1347–61.
  - 39 Halliwell B. Reactive species and antioxidants. Redox biology is a fundamental theme of aerobic life. *Plant Physiol.* 2006;141:312–22.
  - 40 Helgestad J, Storm-Mathisen I, Lie SO. Vitamin C and thiol reagents promote the in vitro growth of murine granulocyte/macrophage progenitor cells by neutralizing endogenous inhibitor(s). *Blut.* 1986;52:1–8.
  - 41 Iwata-Ichikawa E, Kondo Y, Miyazaki I, Asanuma M, Ogawa N. Glial cells protect neurons against oxidative stress via transcriptional up-regulation of the glutathione synthesis. *J Neurochem.* 1999;72:2334–44.
  - 42 Gilgun-Sherki Y, Melamed E, Offen D. The role of oxidative stress in the pathogenesis of multiple sclerosis: The need for effective antioxidant therapy. *J Neurol.* 2004;251:261–8.
  - 43 Herges K, Millward JM, Hentschel N, Infante-Duarte C, Aktas O, Zipp F. Neuroprotective effect of combination therapy of glatiramer acetate and epigallocatechin-3-gallate in neuroinflammation. *PLoS One.* 2011;6:e25456.
  - 44 Di Biase A, Salvati S. Exogenous lipids in myelination and myelination. *Kaohsiung J Med Sci.* 1997;13:19–29.
  - 45 Medina JM, Taberner A. Astrocyte-synthesized oleic acid behaves as a neurotrophic factor for neurons. *J Physiol Paris.* 2002;96:265–71.